

Original article

Clinical and Histopathological Criteria in Libyan Children with Adrenocortical Tumors

Omalmir Fathalla^{1,2*} , Millad Ghawil^{1,2} , Ahmed Eshagrani³ , Nadia Alghazir^{1,2} , Ibtisam Hadid^{1,2} , Amani Farhat¹ , Amani Masoud¹ 

¹Department of Pediatrics, Tripoli University Hospital, Tripoli, Libya

²Department of Pediatrics, Faculty of Medicine, University of Tripoli, Tripoli, Libya.

³Attasami Diagnostic Center, Tripoli, Libya

Corresponding email. miragadafi@yahoo.com

Abstract

Adrenocortical tumors (ACTs) are rare in children, and the extent to which histopathological features can predict clinical behavior remains uncertain. This study aimed to investigate the relationship between histopathological features, surgical approach, tumor size, and outcome by reviewing medical records from 2008 to 2024 of patients treated at Tripoli University Hospital. About 10 ACTs were treated at our institution. We identified them from a database that included demographic and clinical characteristics. The histological features were documented in their medical files. Ten patients were treated for ACTs with a mean age of 2 years (range from 12 months - 17 years). 4 (40%) of them were diagnosed with adrenocortical carcinoma, and 6 patients (60%) were diagnosed with adrenocortical adenoma. In addition, 80% of tumors were on the right side, and 7 patients (70%) survived without evidence of disease, and 3 patients (30%) died. There is an association between histopathological classification, tumor size, and outcome for pediatric ACTs. Pediatric ACTs' histopathological findings, early complete surgical resection is optimal for a good outcome. Genetic evaluation is recommended in patients with ACTs.

Keywords. Adrenocortical Tumors, Pediatric Age, Histopathology Features.

Introduction

Adrenocortical tumors (ACTs) are rare, with a worldwide incidence of 0.3 per million for children younger than 15 years of age [1]. Adrenocortical tumors (ACT) in adulthood and childhood vary in clinical, histopathological, molecular, prognostic, and imaging aspects. In clinical manifestation, adults with ACTs present more frequently with glucocorticoid overproduction (Cushing syndrome). In addition, subclinical tumors are frequently diagnosed late, and it associated with compression symptoms of abdominal mass. Previous studies documented an associated worse result with large tumor size, inadequate surgical resection, and high stages at diagnosis time. Full surgical resection remains the strongest predictor of survival; it does appear to be somewhat beneficial in predicting malignant behavior, consistent with other endocrine neoplasms [2].

ACNs can affect children without known genetic risk factors as well as those with genetic predispositions, including Li Fraumeni syndrome, Beckwith-Wiedemann syndrome, and familial adenomatous polyposis [3,4]. However, the Weiss scoring system is the most widely used and valuable histopathological classification criterion for predicting the behavior of adrenocortical malignancy [5-7]. Both Weiss criteria and Wienceke criteria consider the tumor weight, tumor size, invasion of the inferior vena cava, and other histological features as strong predictors of prognosis in pediatric ACT. Complete surgical resection remains the strongest predictor of survival. Both benign and malignant tumors have the potential to be hormonally active, resulting in increased hormone production that presents as common clinical syndromes [8-9]. With a frequency of 1.5 per million per year, adrenal cortical carcinoma (ACC) is an uncommon malignant counterpart of adrenal neoplasms in children and adolescents [10]. Furthermore, macroscopic criteria such as inferior vena cava invasion and peri-adrenal extension were 100% specific for the diagnosis of ACC [11].

Pediatric ACTs are invariably linked to some constitutional genetic anomaly. The inheritance of a TP53 mutation leads to a predisposition to early cancers, including breast carcinomas, ACC, and brain tumors, which are characteristic of Li-Fraumeni syndrome (LFS) [12]. This study aimed to investigate the relationship between histopathological features, surgical approach, tumor size, and outcome by reviewing medical records from 2008 to 2024 of patients treated at Tripoli University Hospital.

Methods

Study Design and Setting

This study was a retrospective chart review of pediatric patients diagnosed with Adrenocortical Tumors (ACTs) and managed at the Pediatric Endocrinology Department of Tripoli University Hospital, a tertiary referral center for pediatric endocrinology, surgery, and oncology. Data were collected from patients treated and followed up between 2008 and 2024.

Study Population

We included a total of 10 patients with complete medical records (age ≤ 18 years) with confirmed ACTs diagnosed and treated at the center during the study period.

Data Collection

Clinical and demographic data were extracted from medical charts, including: such as age at diagnosis, sex, time between first symptoms and diagnosis, clinical signs and symptoms, tumor position, type of surgery, type of tumor, histopathology findings, and follow-up.

Ethical Considerations

The study was approved by the Ethics Committee of Tripoli University Hospital as a retrospective clinical review. Patient confidentiality was maintained by anonymizing data.

Statistical Analysis

Categorical variables (e.g., sex, tumor type) were analyzed using Fisher's exact test or Chi-square test (as appropriate) to assess associations with outcomes. A p-value < 0.05 was considered statistically significant. Descriptive statistics (means, percentages) were used for demographic/clinical variables.

Results

There were 7 girls and 3 boys with a median age at presentation of 2 years (range, 12 months to 17 years). All patients (100%) had clinical evidence of endocrine hyperfunction at presentation; 10 (100%) with virilization, 5 (50%) with Cushing's syndrome, and 3 (30%) with hypertension. Seven (70%) showed a mixed endocrine presentation: only one patient (10%), a boy, presented with hemihypertrophy. The median interval between the onset of symptoms and diagnosis was 6 months (range, 3 weeks to 18 months).

Male patients had a higher age at presentation (ranging from 4 years to 17 years) with a mean of 12 years in comparison to female patients who presented with an average of 3.5 years (ranging from 1 year to 8 years). In addition, one patient (10%) had a significant family history of malignancy and an underlying genetic predisposition. Radiological investigation demonstrated that the adrenal lesions were present on the right side in 8 (80%) patients and on the left side in 2 patients. All patients underwent primary surgical excision. The tumor size had a median of 4 cm (ranging between 2 and 5 cm), and tumor weight was between 10 and 200 g. Macroscopically, the tumors were circumscribed or encapsulated and occasionally showed areas of hemorrhage without indication of tumor spread to nearby soft tissues or organs in these patients, except presence of a nodular lymph node in one patient who had hemihypertrophy. Furthermore, no evidence of basement vein invasion (Figure 1).

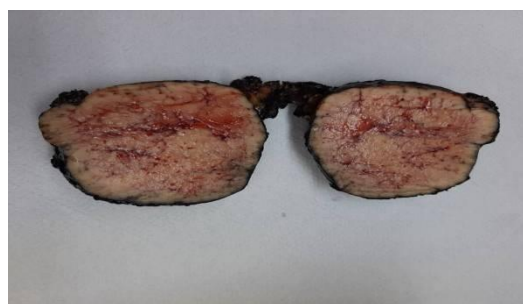

Figure 1. Macroscopic picture for an adrenal tumor in 4 4-year-old boy consists of an oval, yellowish brown, firm tissue solid mass encapsulated, measuring 9x7.4x4.5cm, weighing 20 grams

Histopathological, the majority of tumor cases exhibited a diffuse or solid growth pattern, with varying levels of cellularity, polygonal tumor cells, some of which displayed nuclear enlargement. Atypical mitotic polymorphism was rarely observed, and no atypical mitoses were noted. An immunohistochemistry study revealed that the tumor cells tested positive for melanin A but negative for inhibin. Three cases displayed histological evidence of fibrosis or large fibrous bands, and one case indicated focal tumor necrosis. While four cases showed malignant cells, five patients had small nucleoli (Figure 2). At median follow-up of 2.5 years (range 2 to 5 years), 3 (30%) had died who received chemotherapy after surgery, and 7 patients (70%) survived without evidence of disease, statistically significant, p-value < 0.05 .

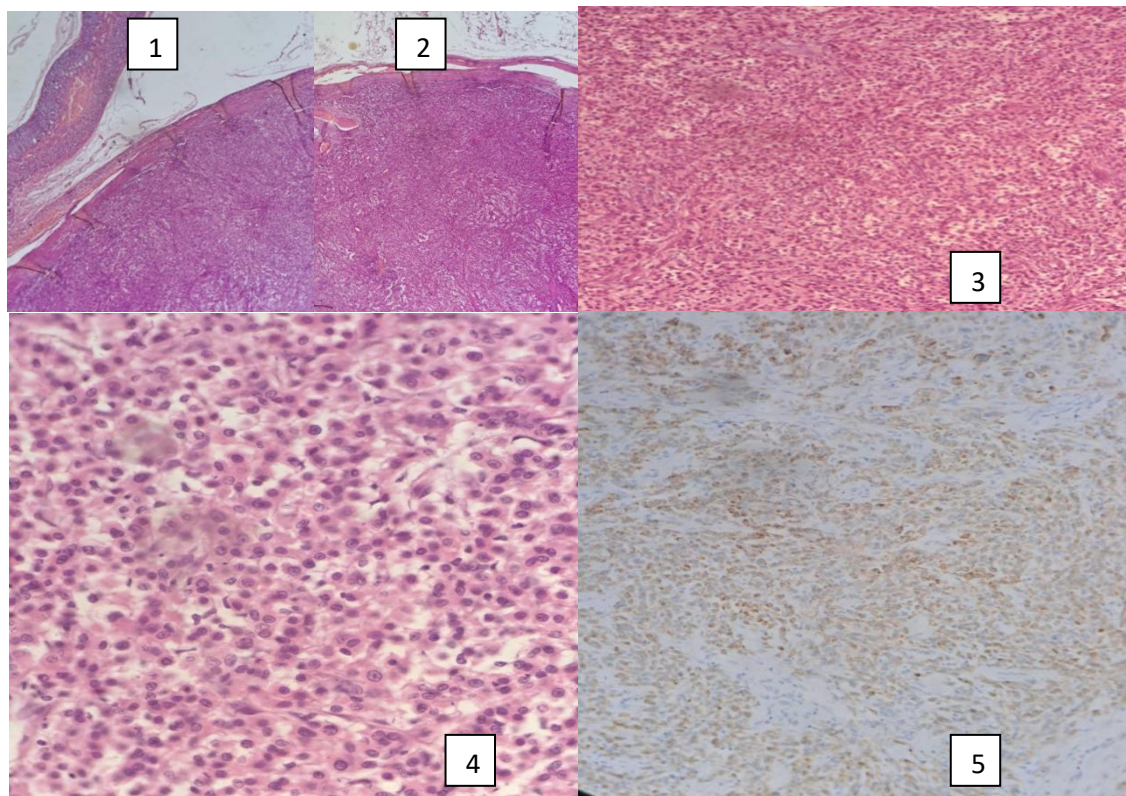


Figure 2. Adrenocortical adenoma. 1&2: Adrenocortical adenoma (&E 100 x), tumor mass, Rim of adrenal gland tissue seen. 3: Adrenocortical adenoma H&E, 200 x} tumor cells arranged in solid nests surrounded by delicate fibrovascular septa. 4: Adrenocortical adenoma (H&E, 200 x), polygonal tumor cells with uniform nuclei and abundant eosinophilic to clear cytoplasm. 5: Adrenocortical adenoma, Melena (A, 200x), tumor cells are positive

Discussion

Adrenal tumors are quite rare in infancy and childhood. It accounts for only 0.2% of all malignant cancers in children and adolescents. In children, the virilizing syndrome or virilizing in association with hypercortisolism is often the primary presentation [13]. Our findings documented that the majority of children who develop ACTs present with endocrine hyperfunction, and the most common presentation is virilization. The site of ACT's tumor is commonly on the right side, with more than 50 % of cases [14]. 80% of our patients had right-sided ACT tumors. Furthermore, the tumor weight, in our data, varied between 10 and 200 g, and this is in the range of the literature, where documented that the tumor weight varied from 7 to 3700 g [14]. The tumor weight and volume are believed to be factors that affect prognosis. Furthermore, the tumor weights exceeding 100 g have been included as criteria for malignancy [14, 15]. According to a multicenter registry investigation, the median interval between first endocrine symptoms and the diagnosis of ACT is 5 months [16], and in our study, the median interval between the onset of symptoms and diagnosis was 6 months.

Xia X et al [16] documented that ACTs death is seen in 38% of patients, who suffer from tumor progression following the diagnosis in about 30 months, and this is similar to the death in our study (30%). Our overall survival rate is 70%, and it is similar to the literature [17]. The features suggestive of malignant behavior in ACTs include a tumor diameter of more than 5 cm, presence of fibrous bands, necrosis, capsular invasion, vascular invasion, disrupted reticulin framework, and a high mitotic rate [18]. These findings with complete surgical excision, which was conducted by an experienced pediatric surgeon's team, were favorable outcomes, and these factors are documented in the literature, even with tumors more than 5 cm in diameter [19]. Therefore, although tumor size generally predicts clinical behavior, small tumors may also result in unfavorable outcomes, particularly when associated with a genetic predisposition syndrome or tumor spread. The assessment of the tumor radiological features with ultrasound and MRI is crucial in preoperative surgical planning. Complete tumor resection is considered curative for most children with ACTs, while rupture of the tumor seems to be associated with early recurrence and poor outcome [20, 21].

Conclusion

Early complete surgical resection is optimal for a good outcome. In addition, there is an association between histopathological classification, tumor size, and outcome for pediatric ACTs. Pediatric ACTs' histopathological findings, Genetic evaluation is recommended in patients with ACTs.

Conflicts of Interest

The authors declare no conflicts of interest.

References

1. Bergada I, Venara M, Maglio S, et al. Functional adrenal cortical tumors in pediatric patients: a clinicopathologic and immunohistochemical study of a long term follow-up series. *Cancer*. 1996;77(4):771-7.
2. Bugg MF, Ribeiro RC, Roberson PK, et al. Correlation of pathologic features with clinical outcome in pediatric adrenocortical neoplasia: a study of a Brazilian population. Brazilian Group for Treatment of Childhood Adrenocortical Tumors. *Am J Clin Pathol*. 1994;101(5):625-9.
3. Figueiredo BC, Stratakis CA, Sandrini R. Comparative genomic hybridization analysis of adrenocortical tumors of childhood. *J Clin Endocrinol Metab*. 1999;84(3):1116-21.
4. Michalkiewicz EL, Sandrini R, Bugg MF, et al. Clinical characteristics of small functioning adrenocortical tumors in children. *Med Pediatr Oncol*. 1997;28(3):175-8.
5. Weiss LM, Medeiros LJ, Vickery AL Jr. Pathologic features of prognostic significance in adrenocortical carcinoma. *Am J Surg Pathol*. 1989;13(3):202-6.
6. Weiss LM. Comparative histologic study of 43 metastasizing and nonmetastasizing adrenocortical tumors. *Am J Surg Pathol*. 1984;8(2):163-9.
7. Tissier F. Classification of adrenal cortical tumors: what limits for the pathological approach? *Best Pract Res Clin Endocrinol Metab*. 2010;24(6):877-85.
8. Chudler RM, Kay R. Adrenocortical carcinoma in children. *Urol Clin North Am*. 1989;16(3):469-79.
9. Michalkiewicz E, Sandrini R, Figueiredo B, Miranda EC, Caran E, Oliveira-Filho AG, et al. Clinical and outcome characteristics of children with adrenocortical tumors: a report from the International Pediatric Adrenocortical Tumor Registry. *J Clin Oncol*. 2004;22(5):838-45.
10. Golden SH, Robinson KA, Saldanha I, Anton B, Ladenson PW. Clinical review: Prevalence and incidence of endocrine and metabolic disorders in the United States: a comprehensive review. *J Clin Endocrinol Metab*. 2009;94(6):1853-78.
11. Ribeiro RC, Pinto EM, Zambetti GP, Rodriguez-Galindo C. The international pediatric adrenocortical tumor registry initiative: contributions to clinical, biological, and treatment advances in pediatric adrenocortical tumors. *Mol Cell Endocrinol*. 2012;351(1):37-43.
12. Faria AM, Almeida MQ. Differences in the molecular mechanisms of adrenocortical tumorigenesis between children and adults. *Mol Cell Endocrinol*. 2012;351(1):52-7.
13. Melo-Leite AF, Elias PC, Teixeira SR, Tucci S, Barros GE, Antonini SR, et al. Adrenocortical neoplasms in adulthood and childhood: distinct presentation. Review of the clinical, pathological and imaging characteristics. *J Pediatr Endocrinol Metab*. 2017;30(3):253-76.
14. Sbragia L, Oliveira-Filho AG, Vassallo J, Pinto GA, Guerra-Junior G, Bustorff-Silva J. Adrenocortical tumors in Brazilian children: immunohistochemical markers and prognostic factors. *Arch Pathol Lab Med*. 2005;129(9):1127-31.
15. Hough AJ, Hollifield JW, Page DL, Hartmann WH. Prognostic factors in adrenal cortical tumors: a mathematical analysis of clinical and morphologic data. *Am J Clin Pathol*. 1979;72(3):390-9.
16. Xu X, Sergi C. Pediatric adrenal cortical carcinomas: histopathological criteria and clinical trials. A systematic review. *Contemp Clin Trials*. 2016;50:37-44.
17. Sakoda A, Mushtaq I, Levitt G, Sebire NJ. Clinical and histopathological features of adrenocortical neoplasms in children: retrospective review from a single specialist center. *J Pediatr Surg*. 2014;49(3):410-5.
18. Papotti M, Libe R, Duregon E, et al. The Weiss score and beyond—histopathology for adrenocortical carcinoma. *Horm Cancer*. 2011;2(6):333-40.
19. Mayer SK, Oligny LL, Deal C, et al. Childhood adrenocortical tumors: case series and reevaluation of prognosis—a 24-year experience. *J Pediatr Surg*. 1997;32(6):911-5.
20. Ribeiro RC, Sandrini-Neto R, Schell MJ, Lacerda L, Sampaio GA, Cat I. Adrenocortical carcinoma in children: a study of 40 cases. *J Clin Oncol*. 1990;8(1):67-74.
21. Sabbaga CC, Avilla SG, Schulz C, Garbers JC, Blucher D. Adrenocortical carcinoma in children: clinical aspects and prognosis. *J Pediatr Surg*. 1993;28(7):841-3.